

Human Histology and Persistence of Various Injectable Filler Substances for Soft Tissue Augmentation

Gottfried Lemperle, M.D., Ph.D.,¹ Vera Morhenn, M.D.,² and Ulrich Charrier, M.D.³

^{1,2}San Diego, CA, USA

³Frankfurt, Germany

Abstract. An increasing number of soft tissue filler substances have been introduced to the beauty market outside the U.S. which lack experimental and clinical data in support of their claim. Ten commercially available filler substances were examined for biocompatibility and durability: 0.1 cc of each substance was injected deep intradermally into the volar forearm of one of the authors and observed for clinical reaction and permanence. At 1, 3, 6, and 9 months the test sites were excised, histologically examined, and graded according to foreign body reactions classification. Collagen (Zyplast) was phagocytosed at 6 months and hyaluronic acid (Restylane) at 9 months. PMMA microspheres (Artecoll) had encapsulated with connective tissue, macrophages, and sporadic giant cells. Silicone oil (PMS 350) was clinically inconspicuous but dissipated into the tissue, causing a chronic foreign body reaction. Polylactic acid microspheres (New-Fill) induced a mild inflammatory response and had disappeared clinically at 4 months. Dextran microspheres (Reviderm intra) induced a pronounced foreign body reaction and had disappeared at 6 months. Polymethylacrylate particles (Dermalive) induced the lowest cellular reaction but had disappeared clinically at 6 months. Polyacrylamide (Aquamid) was well tolerated and remained palpable to a lessening degree over the entire testing period. Histologically, it dissipated more slowly and was kept in place through fine fibrous capsules. Polyvinylhydroxide microspheres suspended in acrylamide (Evolu-

tion) were well tolerated, slowly diminishing over 9 months. Calcium hydroxylapatite microspheres (Radiance FN) induced almost no foreign body reaction but were absorbed by the skin at 12 months. Host defense mechanisms react differently to the various filler materials, but all substances—resorbable or nonresorbable—appeared to be clinically and histologically safe, although all exhibit undesirable side effects. Since the mechanism of late inflammation or granuloma formation is still unknown, early histological findings are not useful in predicting possible late reactions to filler substances.

Key words: Dermal filler substances—Soft tissue augmentation—Aquamid—Artecoll—Dermalive—Evolution—New-Fill—Radiance FN—Restylane—Reviderm intra

In recent decades, dermal filler substances consisting of highly viscous fluids [33,40,53] or polymer particle suspensions [21,37] have been injected beneath wrinkles and acne scars [8,31]. These substances are useful for the correction of congenital or traumatic facial, bony, and soft tissue defects [10], and in patients suffering from scleroderma, Romberg's disease, facial wasting, or lipodystrophy following AIDS treatment [2,11,57]. Additional indications are unilateral paralysis of vocal cords [12,24,28], augmentation of the lip and soft palate in cleft lip patients, anophthalmic orbits [10], or enophthalmus. Other potential applications as bulking agents are lower esophageal sphincter in gastroesophageal reflux patients [22,48], and bladder neck or anal sphincter in patients suffering from urinary [5] or fecal incontinence [27,63].

Animal studies [38] and clinical trials [15,19] have shown good acceptance and short- and long-term

Presented at the 33rd Annual Meeting of the Association of German Plastic Surgeons in Heidelberg, Germany, September 21, 2002

Correspondence to Gottfried Lemperle, M.D., Ph.D., Division of Plastic Surgery, University of California, San Diego; *email:* glemperle@aol.com

efficacy in accordance with the chemical structure and surface characteristics of the microparticles. Resorbable materials such as collagen, hyaluronic acid [19,36,49], polymethylacrylate (PMA) [6], dextran [20], or polylactic acid [2] are removed by phagocytosis over a period of 3–12 months depending on the amount and type of bulking agent implanted. Permanent fillers such as paraffin [33], fluid silicone [11,17], Teflon [34], or silicone particles [21] have an irregular surface and cannot be phagocytosed but may eventually form foreign body granulomas due to “frustrated macrophages” [20]. Microspheres below the size of 15 microns [44,61] are generally phagocytosed and may be transported to local lymph nodes. Larger microspheres from nonresorbable polymers with a smooth surface [35,38,51] are encapsulated with fibrous tissue and escape phagocytosis. Clinically, all injected fluids [45,59] and particles [54,56] have been shown to cause foreign body granulomas in a small percentage of patients. Until the mechanism of granuloma formation is fully understood, the chance of development is not predictable.

The ideal soft tissue filler substance for wrinkles, skin defects, and sphincter

- is biocompatible and safe
- is stable at the implantation site
- keeps its volume and remains pliable
- does not cause protrusion of the skin or mucosa
- induces minimal foreign body reaction
- will not be removed by phagocytosis
- has no migration potential to distant locations
- does not cause foreign body granuloma.

As a percentage of wet weight, the human skin is composed of collagen (27–39%), elastin (0.2–0.6%), glycosaminoglycans (0.03–0.3%), and 60–72% water. The goal of this study was to confirm histocompatibility and permanence of various filler substances under investigation. For some products there exist no published scientific reports on biocompatibility, histology, or clinical studies.

Materials and Methods

During the past 4 years, four 0.1-cc blebs of 10 different dermal filler substances have been injected deep intradermally into the volar skin of a forearm, next to an existing scar. The injection sites were inspected weekly and clinical changes were recorded and photographed. Each raw of the different implants was excised after 1, 3, 6, or 9 months. At least four sections were cut from each implantation site at different levels for histological examination. The sections were stained with hematoxylin–eosin or Masson trichrome and evaluated in Frankfurt. An independent pathologist (U.C.) was blinded, receiving the histological

slices numbered only, and being unaware of the material involved.

A classification of foreign body reactions, established by Duranti et al. [19], was applied to each histological slide. The grading was performed on at least four slices of the same specimen.

- Grade I: slight reaction with a few inflammatory cells
- Grade II: clear inflammatory reaction with one or two giant cells
- Grade III: fibrous tissue with inflammatory cells, lymphocytes, and giant cells
- Grade IV: granuloma with encapsulated implants and clear foreign body reaction

The following commercially available filler materials were bought and injected in Europe:

1. Zyplast, a suspension of 3.5% crosslinked bovine collagen, purchased from Collagen Aesthetics, Inc., Fremont, CA
2. Restylane, a suspension of 2.0% crosslinked hyaluronic acid (HA) produced biotechnologically from *Streptococcus equi* [36,47,50] in saline, purchased from Q-Med AB, Uppsala, Sweden
3. Artecoll, a suspension of 20% microspheres (40 μm) of polymethylmethacrylate (PMMA) in 3.5% bovine collagen solution [35,37], obtained from Artes Medical Inc., San Diego, CA
4. PMS 350, medical grade silicone fluid (dimethylpolysiloxane) of 350 centistoke viscosity, purchased from Vikomed, Meinerzhagen, Germany
5. New-Fill, which comes as a powder of poly-L-lactic acid (L-PLA) microspheres (2–50 μm) to prepare a 4.5% suspension in 2.7% methylcellulose [2], purchased from Biotech Industry S.A., Luxembourg
6. Reviderm intra, a suspension of 2.5% dextran microspheres (40 μm Sephadex) [20] in 2.0% hyaluronic acid (2.5 MDa) of bacterial origin (Rofilan), obtained from Rofil Medical International N.V. (RMI), Breda, The Netherlands
7. Dermalive, a 240% suspension of hydroxyethylmethacrylate (HEMA) fragments in 1.14% crosslinked hyaluronic acid of bacteriological origin [6], purchased from Dermatech S.A., Paris, France
8. Aquamid, a clear 5% crosslinked gel from polyacrylamide (PAAG) [42], purchased from Contura International S.A., Montreux, Switzerland
9. Evolution, a suspension of 6% polyvinylhydroxide (PVOH) microspheres (5–80 μm) in 2.5% polyacrylamide gel, purchased from Laboratoires ProCytech, Bordeaux, France
10. Radiance FN, a suspension of 30% calcium hydroxylapatite microspheres (25–40 μm) in a carboxymethyl-cellulose gel [9], purchased from BioForm Inc., Franksville, WI

Results

All four implant sites in the human forearm could easily be identified after 1 and 3 months; however, not all implants could be visualized after 6 and 9 months. In the latter cases, the whole area was excised and sectioned 5–10 times in order to identify microscopic traces of the implant.

Zyplast

The tissue sections obtained from human skin showed the presence of many macrophages and invading capillaries at the circumference of the implants at 1 month. This process goes along with slow resorption of the crosslinked eosinophilic opaque material with gradual and scarce infiltration of inflammatory cells, and little or no deposition of structures, which resemble new collagen fibers at 3 months [32]. At 6 months, no residue of cell-free Zyplast could be found in the human skin. The histological reactions were evaluated according to the Duranti scale (Fig. 1).

Restylane

The clear hyaluronic acid gel induced erythema and swelling in the human skin for 2 days. Clinically, Restylane and all other tested crosslinked hyaluronic acid products disappeared from the skin within 4 months. Histologically, the blue stained hyaluronic acid showed little foreign body reaction (Fig. 2) but was slowly degraded by macrophages. Some macrophages and rare giant cells were apparent in the human skin at 3 months [19]. Clusters of these cells could still be found after 6 months; however, no residue could be identified at 9 months.

Artecoll

At 1 month, each individual microsphere was separated from adjacent microspheres by a thin layer of eosinophilic material representing collagen fibers (Fig. 3). The implants were discrete and well circumscribed within the soft tissue. The peripheral regions of these foci had infiltrated to a depth of 2–3 microspheres and contained macrophages (1 per approximately 15 beads) and few multinucleated giant cells. The centers of the lesions were cell free and separated through fibrin fibers only. At 3 and 6 months, isolated giant cells extended deeper into the lesions (Fig. 4).

The implanted denatured collagen appeared to be resorbed at 3 months. New collagen deposits, evident at 1 month, increased the spaces between individual microspheres. The number of inflammatory cells was small at all times and indicates that collagen and

microspheres induce a minimal immunogenic response.

The relative size of the palpable Artecoll lesions in human skin remained unchanged over 9 months (Fig. 5), suggesting that dissipation of microspheres into the surrounding soft tissue or migration to adjacent lymph nodes does not occur (Fig. 3).

PMS 350 Silicone Fluid

PMS 350 is a colorless oil with a low viscosity, 350 times that of water (1 centistoke = viscosity of water), but with high chemical stability. Immediately after injection, PMS 350 dispersed into the surrounding tissue in form of millions of microdroplets (Fig. 6). At 1 month, each microdroplet, about 20–100 microns in size, was encapsulated by a monolayer of fibroblasts and collagen fibers. Macrophages and giant cells, which phagocytosed the foamy, translucent, birefringent material, were found at 3 and 6 months. Asteroid bodies in the cytoplasm of macrophages and giant cells were typically seen after phagocytosis of the silicone fluid. At 9 months, granulomatous nodules in the dermis and subcutaneous tissue were surrounded by strands of fibrous tissue.

New-Fill

The PLA implants were well palpable for the first 3 months but had disappeared from the human skin at 4 months. In the refrigerator, PLA microspheres with diameters between 2 and 50 μm , were still recognizable as microspheres 2 weeks after suspension, and were partly hydrolyzed and deformed at 1 and 3 months.

Histologically, a fine capsule could be observed around the implant throughout. At 3 months, the microspheres had remained spherical and were surrounded by macrophages and some lymphocytes (Fig. 7). At 6 months, most microspheres showed a porous surface structure, were fissured and sometimes deformed, and were surrounded by macrophages and small giant cells. Their pseudopodia infiltrated the surface of some microspheres but did not degrade the activity of these cells. The PLA was likely dissolved by hydrolysis and extracellular enzymes [3,60] and subsequently broken down by macrophages. At 9 months, the degradation of PLA microspheres was completed. At 9 months, no remnant of cicatricial fibrosis was found after total disappearance of PLA residues in the human skin. This finding illustrates the excellent biocompatibility of PLA.

Reviderm intra

The injection of dextran beads caused swelling and redness, which continued for 10 days—possibly due

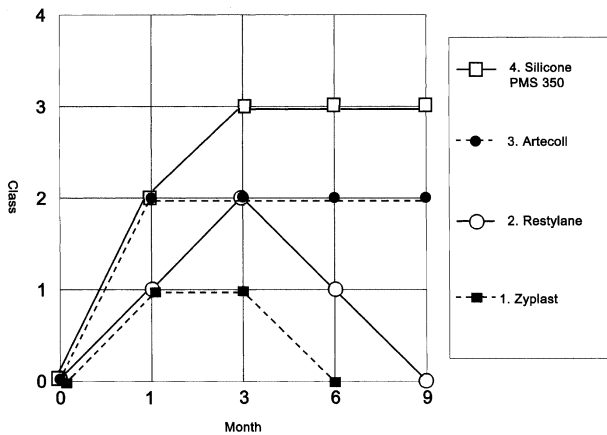


Fig. 1. The Duranti-classification reflects the extent of histological foreign body reaction at certain times. Class 2 is determined by a few giant cells.

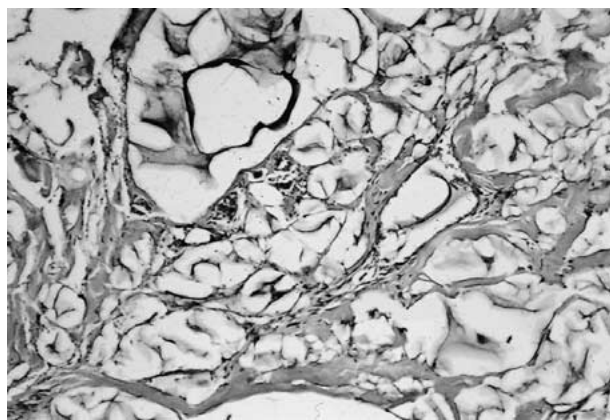


Fig. 2. Restylane at 1 month. Minor cellular reaction of the surrounding tissue, scattered macrophages and giant cells, no immune response, and good biocompatibility. HE $\times 100$.



Fig. 3. Artecoll at 1 month. The two strands of implants here have a diameter of a 26 G needle and are still packed in a fibrin network with some macrophages and giant cells. Masson trichrome $\times 20$.

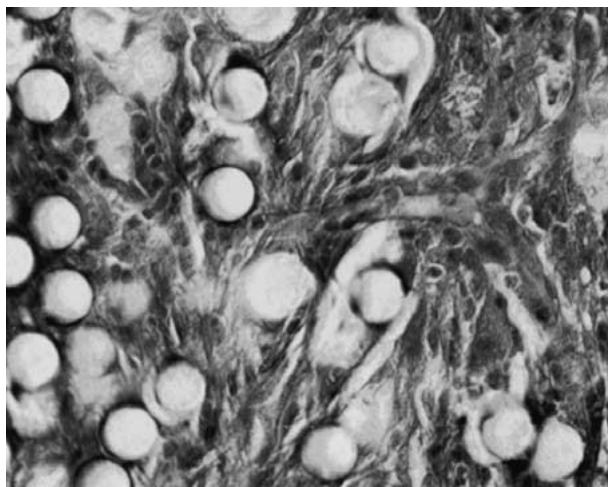


Fig. 4. Artecoll at 6 month. All microspheres are encapsulated by connective tissue and some macrophages. Duranti Grade II. Masson trichrome $\times 400$.

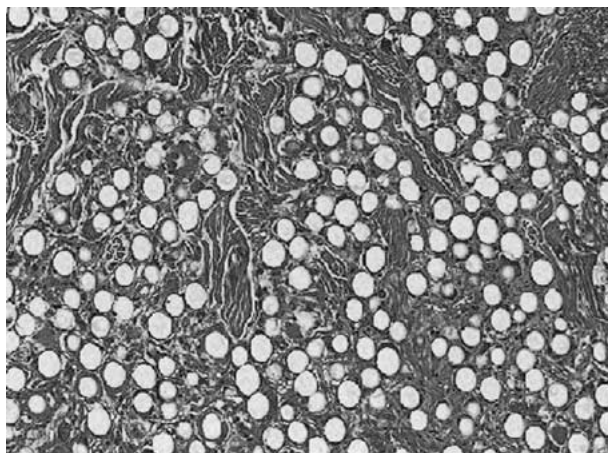


Fig. 5. Artecoll at 10 years. The microspheres are still intact and surrounded by collagen fibers, fibroblasts, some macrophages, and isolated giant cells. Masson trichrome $\times 100$.

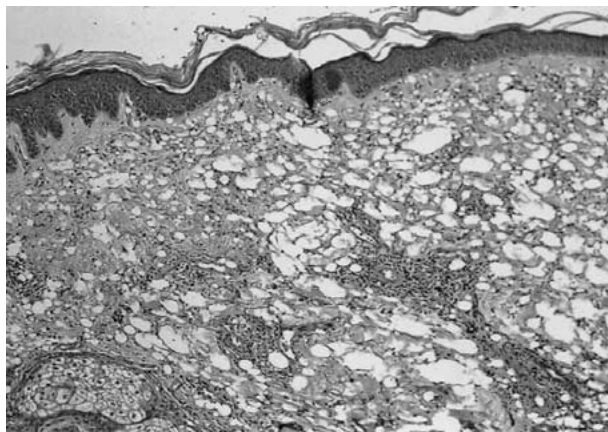


Fig. 6. PMS 350 silicone gel at 1 month. The gel has dissipated into millions of microdroplets, which are surrounded by macrophages and lymphocytes. HE $\times 100$.

to the toxic effect of free dextranomers. Edematous swelling of the implants continued for more than 3 months. The palpable deep dermal implant began to disappear at 4 months and was no longer palpable at 6 months.

Histologically, the 40- μm dextran beads produced the greatest amount of granulation tissue among all injectables tested. At 1 month, the hydrophilic microspheres were swollen and measured up to 75 μm in diameter (Fig. 8); some were broken apart and surrounded by foamy macrophages and small giant cells. The hyaluronic acid carrier had early separated from the beads and was found in pools, surrounded by a rim of giant cells (Fig. 9). At 3 months, only few elastic fibers could be seen; instead there were great numbers of macrophages and giant cells, which enveloped and tried to phagocytose the beads. The surface of the dextran beads began to show irregularities at 6 months and total disintegration at 9 months. It ranged to the top of the Duranti scale among the resorbable implants (Fig. 10), possibly due to the carrier from an undisclosed source of hyaluronic acid (Rofilan), which has been crosslinked with a plant extract.

Dermalive

The hydroxyethyl-methacrylate (HEMA) fragments began to disappear in the human skin at 4 months and were no longer palpable at 6 months.

Histologically, they showed the least cellular reaction of all implants. The polygonal, translucent, and irregular particles, 20–120 μm in size, which appeared like clear broken glass gravel, were packed in clusters, with minimal ingrowth of fibrous tissue, cells, and blood vessels (Fig. 11). Only a fine network of elastic fibers and occasionally macrophages were found, but there were no apparent capillaries and no strong fibrous capsule. The hyaluronic acid was separated and surrounded by macrophages, which had disappeared at 3 months. At 9 months, only a few small clusters of Dermalive with rounded corners and ridges, many macrophages, and lymphoid cell clusters could be detected. The few giant cells contained abundant asteroid bodies in their cytoplasm. Some pointed particles had a tendency to irritate the surrounding soft tissue, which showed clear evidence of low grade inflammation. However, only about one tenth of the implant volume consisted of cells and fibers (Fig. 11).

Aquamid

The clear gel of polyacrylamide was implanted into human skin at four sites. Used in breast augmentation in Ukraine and China, it had a viscosity of 1045 centistoke. Since no anesthetic is added, the injections into human skin caused a burning sensation for ~ 20 sec. This was likely due to the cross-linked gel's pH of

7.0 to 9.0. On examination, the implants revealed no reaction and were still palpable at 9 months, but decreasing in size.

Histologically, acrylamide gel was difficult to detect at 1 month. The injected, non stainable transparent gel produced only a fine fibrocellular capsule (Fig. 13), as expected from the literature [14,42]. At 3 months, no further histopathological reaction occurred outside the implant site, such as foreign body reaction. At 6 and 9 months, Aquamid had dispersed into the skin and was surrounded by macrophages and fibroblasts (Fig. 12). The histological reaction resembled that of injected fluid silicone. In small quantities, such as a slim strand beneath a wrinkle, the gel appeared to be slowly absorbed, without visible foreign body reaction. Therefore, the manufacturer's claim of "lifelong permanence" seems to be dependent on the amount of implanted acrylamides.

Evolution

Clinically, the implant made of polyvinylhydroxide microspheres suspended in acrylamide gel resembles Artecoll. It was not painful during injection as was Aquamid. Because of evaporation through the polyethylene syringe, the water content of the material was already diminished at the time of purchase. The implants were well visible and diminishing palpably over the whole course of 9 months. Histological examination showed the beads, most of them 30–40 μm in diameter, within the clear acrylamide gel (Fig. 13) surrounded by an almost invisible fibrous capsule. Each droplet, 3–5 mm in size, was encapsulated with a very fine layer of fibroblast and fibers without ingrowth into the implant. No foreign body reaction was detectable. A few single microspheres outside the implant site were covered with a fibrin layer or had attached macrophages and fibroblasts. At 6 and 9 months, most of the carrier gel had been absorbed and was replaced at the outer layers by granulation tissue. At 9 months, the implant was totally infiltrated by macrophages, fibroblasts, and giant cells (Fig. 14), which resembled the tissue ingrowth of PLA at 3 months. The surface of the microspheres was still intact after 9 months.

Radiance FN

Clinically, the subdermal implants in the forearm were swollen for 3 days. Within 1 month, the palpable implant diminished to half its prior size and became whitish and shining through the skin. The hard nodules diminished further in size and disappeared clinically at 9 months from the skin.

Histologically, Radiance microspheres stimulate almost no foreign body reaction. The 1-month sample had to be embedded in PMMA like bone tissue because the implant could not be cut by conventional

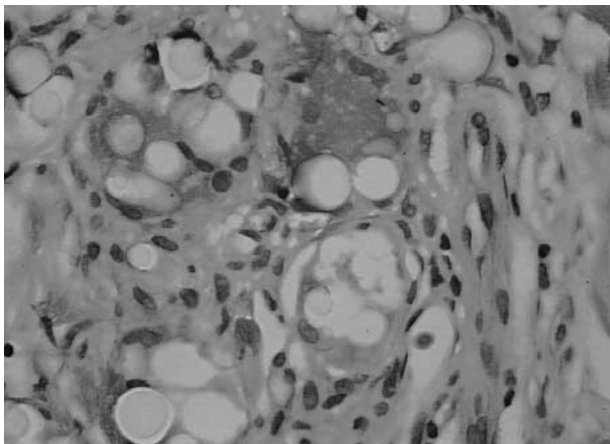


Fig. 7. New-Fill at 3 months. Macrophages and giant cells are surrounding the PLA microspheres and are filled with phagocytosed PLA material. HE $\times 400$.

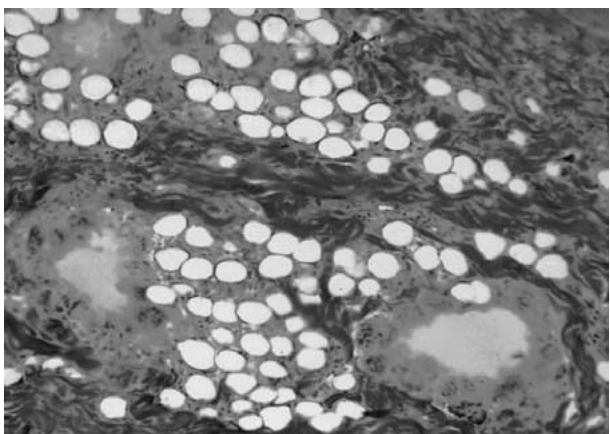


Fig. 8. Reviderm at 1 month. Most dextran beads (its empty vacuoles) are surrounded by macrophages and giant cells with conspicuous foamy cytoplasm. The HA carrier is separated from the beads and surrounded by a rim of giant cells. Masson trichrome $\times 100$.

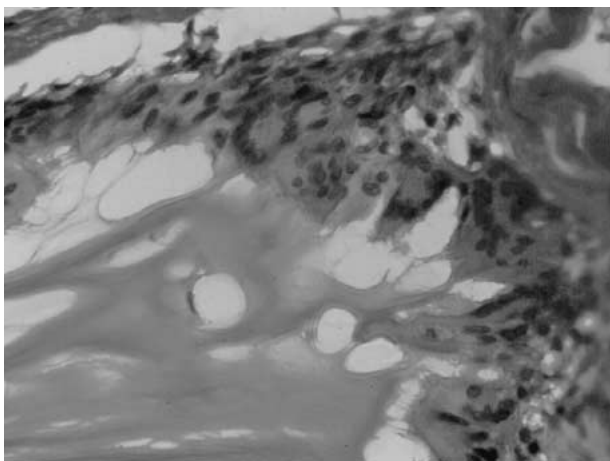


Fig. 9. The HA carrier of RevidermTM at 1 month has separated early from the beads and is slowly phagocytosed by a rim of multinucleated giant cells. Masson trichrome $\times 400$.

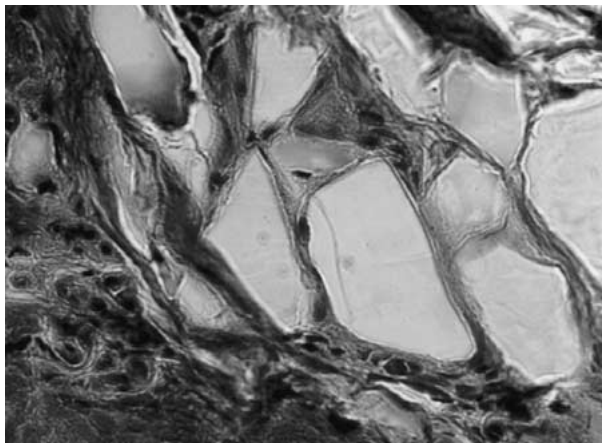


Fig. 10. The Duranti classification reflects the extent of histological foreign body reaction. Class 3 is defined by infiltrating lymphocytes and giant cells. Zeroplast consists of PMMA beads suspended in Rofilan. L40 are PLA beads suspended in collagen.

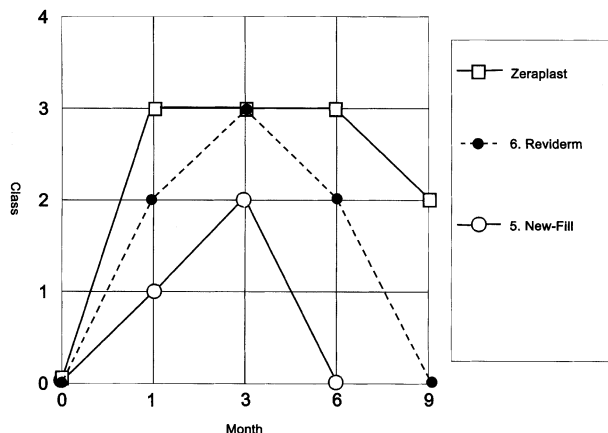


Fig. 11. Dermalive at 3 months. The PMA particles are packed and cause little foreign body reaction. Invading macrophages and some giant cells gather at edges and corners. Masson trichrome $\times 400$.

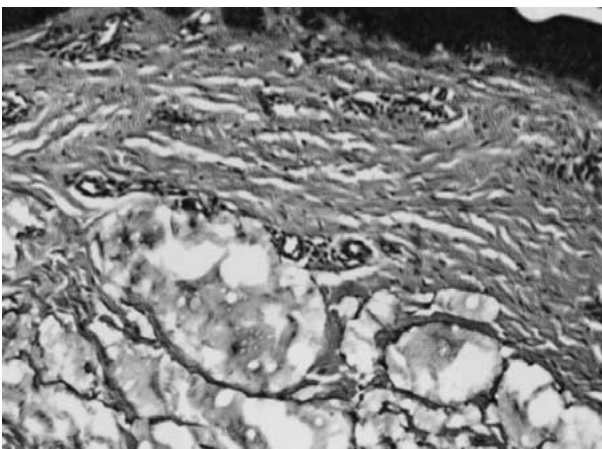


Fig. 12. Aquamid at 6 month. The big droplets have been dispersed into millions of mini-droplets, surrounded by fine fibrous capsules with minimal foreign body reaction. This picture resembles fluid silicone. HE $\times 100$.

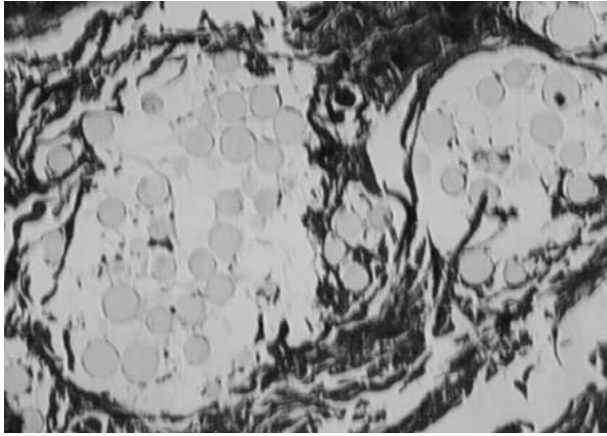


Fig. 13. Evolution at 3 months. Most PVH microspheres are still suspended in acrylamide gel, which results in a fine fibrous capsule without foreign body reaction. Aquamid induces the same inconspicuous histological reaction at that time. Masson trichrome $\times 100$.

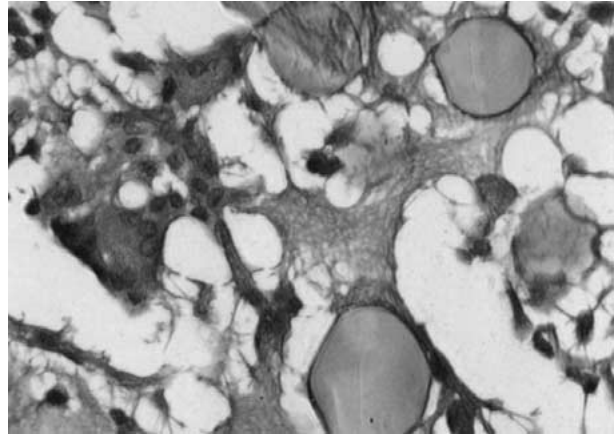


Fig. 14. Evolution at 9 month. Macrophages and multinucleated giant cells have phagocytosed most of the acrylamide carrier. At that stage, each single microsphere is encapsulated with fibrin and some macrophages. Masson trichrome $\times 400$.

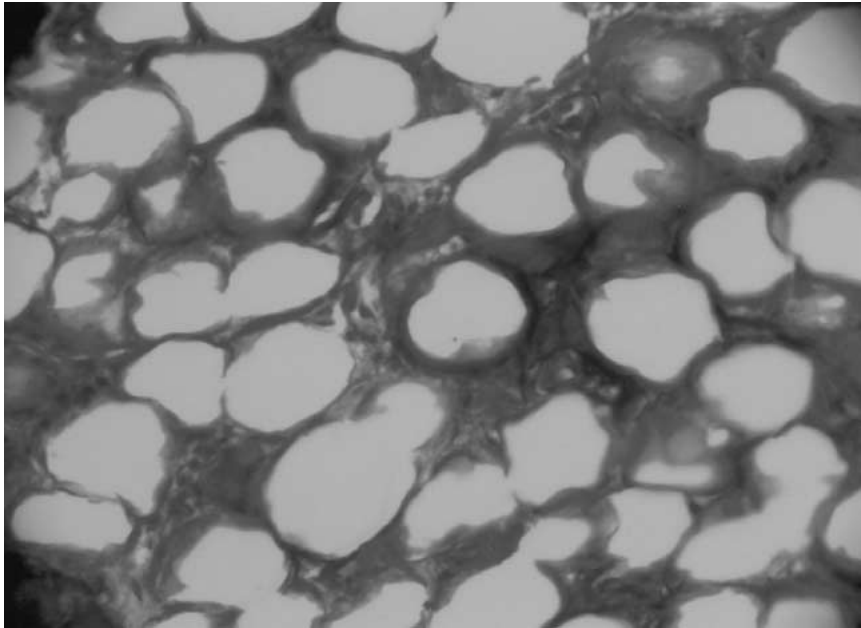


Fig. 15. Radiance at 3 months. The calcium microspheres are packed, the interstitium is filled with fibrin and scattered fibroblasts and macrophages. Masson trichrome $\times 100$.

methods. The beads were packed and surrounded by some fibrin fibers but little cellular tissue. At 3 months, a method of rapid decalcification was applied prior to cutting and staining. The beads were still packed (Fig. 15) and tissue ingrowth started from the fine outer capsule of the implant. The main "interstitium" still consists of fibrin fibers and few cellular elements like fibroblasts and flattened macrophages. No vascularity could be detected. At 6 months, the whole implant is surrounded by a fine fibrous capsule and single microspheres are encapsulated by a thin fibroplastic stroma with flattened cells. At 9 months, the voids are much smaller in

diameter and the microspheres deformed and slowly adsorbed (Fig. 16). Since few macrophages were seen it is suggested that calcium hydroxylapatite microspheres are degraded by enzymatic breakdown rather than phagocytosis.

Discussion

Collagen Gel

Bovine collagen is the "gold standard" for all other newly introduced injectables. To date, Zyderm

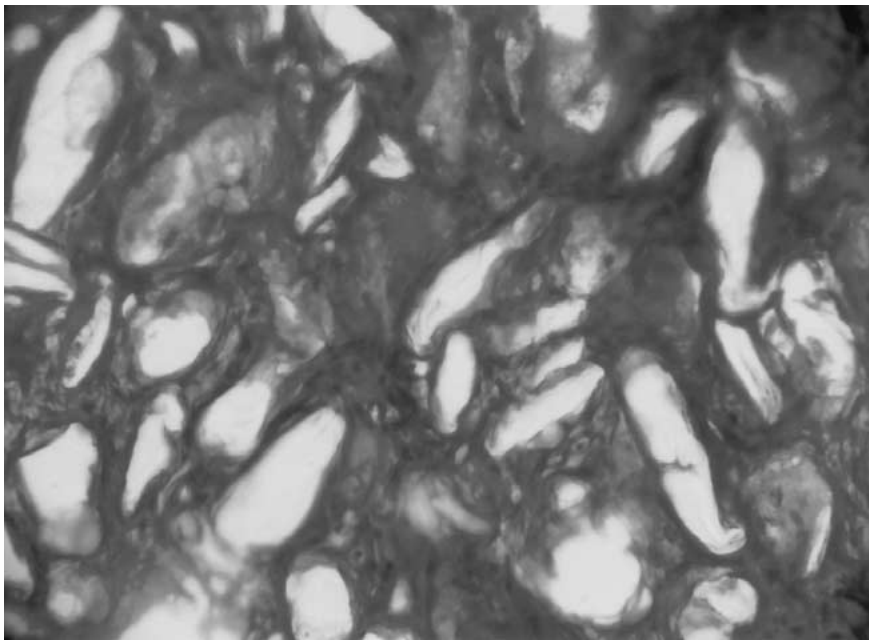


Fig. 16. At 9 months, the Radiance microspheres appear deformed and partly degraded, probably by osteolytic enzymes and not by phagocytosis. Masson trichrome $\times 100$.

and Zyplast have been the only FDA-approved dermal filler substances in the U.S. for more than 20 years. The limited longevity of Zyderm and Zyplast, ease of use, low incidence of allergic reactions ($< 1\%$), and safety are well established [32]. Late granuloma formation occurs at a lower rate [26,45] than with slowly resorbable gels and particulate materials.

Hyaluronic Acid Fluids

Human hyaluronic acid, a polysaccharide of 4–5 kDa molecular weight has a half-life of only 1–2 days. It forms the cellular interstitium of the dermis and creates volume by binding water. A human body contains approximately 15 g HA. To avoid an early breakdown, injectable hyaluronic acids have to be crosslinked. The HA in Restylane has a molecular weight of 1×10^6 Da, but 0.5% or every 200th amino acid of the molecule is crosslinked (“stabilized”) with a neighbor molecule. The company claims that it contains a suspension of 1×10^5 HA particles of 40–60 μm size in HA fluid. A similar product, Perlane, is said to contain 8×10^3 gel particles/ml of approximately 100 μm in diameter, and Fine Lines approximately 2×10^5 gel particles/ml of 20–30 μm in diameter. These gel particles, however, cannot be seen under the microscope. Residues from the process of fermentation of *Streptococcus equi* ($> 107 \mu\text{g/ml}$ [41]) may induce allergies to this bacterial protein in certain patients. Acute and late inflammatory skin reactions have been occasionally reported [13,25,39,41].

PMMA Microspheres

These microspheres showed the most stable appearance throughout the experiment. Once injected, the PMMA microspheres cannot be broken down by enzymes, since a methyl group in the alpha-position stabilizes the molecule. Interestingly, the volume of the injected collagen (80%) remained stable in the implant over the years (Fig. 5). The microspheres act merely as a scaffold and a stimulus for constant connective tissue production. Here, the implant carrier is truly “replaced” by the body’s own tissue. In contrast to other “dead” permanent filler substances like acrylamide or Radiance, the ingrowth of connective tissue creates a “living” implant.

Artecoll gives predictable results; however, at the same time it is “non-forgiving” when mistakenly implanted in an incorrect plane. To avoid technical mistakes, introductory courses and a careful learning curve are required. It may induce granuloma formation in very rare instances [35], as all other substances will do in certain patients. Artecoll has a 10-year history [35] and has been used in more than 200,000 patients worldwide outside the U.S.

Another injectable implant of PMMA microspheres, 1–80 μm in diameter but suspended in Mg-carboxy-gluconate (Metacril), is produced and distributed in Brazil [47].

Silicone Fluid

As we know from ruptured breast implants, silicone gel causes the rarest foreign body reaction among the

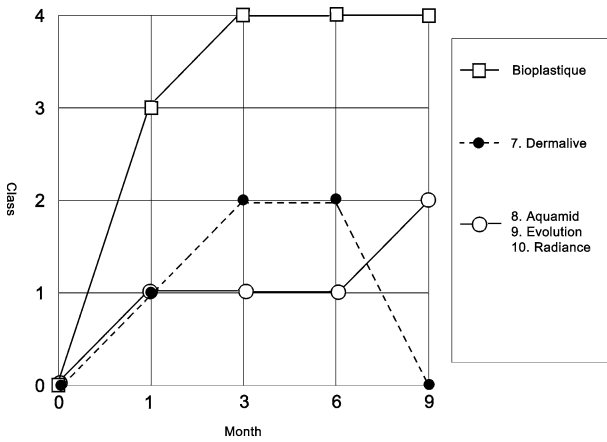


Fig. 17. Duranti classification reflects the extent of foreign body reaction at certain times. Class 4 defines granuloma formation. Bioplastique is a suspension of silicone particles in PVP. Embosphere are soft microspheres of trisacrylgelatin used for tumor embolization [4].

filler materials. In most patients, silicone gel remains very soft and is encapsulated by only a very thin layer of fibroblasts. The lack of fibrous capsule formation may lead to the displacement of larger quantities, aided by gravity, which may migrate downwards from the glabella to the cheeks and from the nasolabial folds to beneath the chin. In time, the implant can harden through ingrowth of connective tissue, macrophages, and foreign body cells, which form a granuloma [53].

The reputation of “medical grade” *silicone fluid* has been damaged by five facts: (1) the use of large quantities, e.g., in breast augmentation or facial dystrophies [17,18], has led to deformation; (2) the possibility of gravity induced “migration” in patients with very lax skin and subcutaneous tissue; (3) the possibility of late (5–20 years) granuloma (siliconoma) formation; (4) the substitution of cheaper, non-medical-grade silicone fluids by nonprofessionals; and (5) the lack of experience of most physicians in the treatment of rare cases of late siliconoma. Though difficult to remove surgically, siliconomas respond favorably to multiple injections of corticosteroid [7] or antimetabolic agents [58]. The wrinkles and lips of thousands of patients in Europe and Asia have been treated successfully with the micro-droplet technique with small amounts of medical-grade silicone fluid. On the other hand, hundreds of women required total mastectomy due to chronic inflammation of large amounts of silicone oil injected directly into the breast. As so often in medicine, success depends on the right dosage, volume, and knowledge of side effects.

Polylactic Acid Microspheres

Polyactic acids do not occur naturally, but were first synthesized by French chemists in 1954. PLA and

polyglycolic acid (PGA) have been used safely in suture materials (Vicryl, Dexon), in resorbable plates and screws, in guided bone regeneration, in orthopedic, neuro-, and cranio-facial surgery, and as drug delivery devices [60]. PLA does not stimulate the natural production of collagen [2], but causes a foreign body reaction, characterized by macrophages, giant cells, and some elastic fibers. The PLA polymer New-Fill disappeared within 6 months, probably due to extracellular hydrolysis, ester cleavage, and the catalytic effect of hydrosoluble acid monomers formed in the polymer matrix during degradation [3]. Whether the mild inflammatory response elicited by PLA can be ascribed to degradation activity of macrophages is not clear.

The degradation rate of PLA polymers in vivo is said to be almost twice that in vitro [60]. Our experiments with microspheres, however, have shown the opposite. After refrigeration for 6 months, the microspheres in their fluid cellulose carrier had dissolved totally, whereas the microspheres in living tissue were still recognizable as round with irregular surface. The degradation of different PLAs is affected dramatically by the amount of glycolic units in the lactic acid chains [60]. Degradation only appears when the molecular weight of the PLA decreases below 20×10^3 Da. The PLA in New-Fill has a molecular weight of 170×10^3 Da. Nine months after implantation, no polymer residue or remnant cicatricial fibrosis were found, confirming the good biocompatibility of PLA microspheres. Since PLAs contain no animal proteins, allergies are not expected; however, late granulomas have been reported as with any other filler substance.

Dextran Microspheres

Dextran is the substrate of chromatography columns (Sephadex) used for the separation of proteins. Dextran molecules of 40,000 and 80,000 Da are used as plasma expanders, since dextran molecules $< 20,000$ Da will be filtered by the kidney. Dextran beads of 100 μ m in diameter were found intact 2 years after implantation in the back skin of rats. Eppley et al. [18] emphasized that the positive surface charges of dextran beads apparently attracted macrophages. The macrophages in turn release TGF-beta and interleukins, which stimulate fibroblasts to produce collagen fibers. After extensive resorption of the dextran beads at 9 months, however, little or no cicatricial residue could be detected at the implantation sites in these studies. Dextran beads of 100 μ m in diameter (Deflux, Q-Med, Uppsala, Sweden) are currently used in clinical trials for the treatment of stress urinary incontinence.

HEMA Fragments

Dermalive is a by-product of the manufacture of intraocular lenses and was introduced in the European

market in 1998. Because of a rather high incidence of granuloma formation, it is now used mainly in the form of Dermalive with HEMA fragments 80–110 μm in size for deep dermal and epiperiosteal implantation. Inside the implant, the HEMA particles were packed closely, probably due to diminished viscosity of the carrier medium hyaluronic acid. This carrier dissipated from the particles just after implantation of Dermalive and was found outside of the clusters of particles.

The great advantage of collagen as a suspension medium for filler substances is its high viscosity, which keeps the particles or microspheres apart weeks after implantation. Since little host tissue formation is stimulated, more Dermalive has to be injected compared to other fillers. On the other hand, HEMA has a free OH-group, which should stimulate macrophage activity. Endogenous esterases in serum and liver break down HEMA. Interestingly, the amount of tissue reaction is no indication for the rate of granuloma formation. In the studies described here, Dermalive evoked the least new tissue formation but clinically causes a rather high rate of granuloma formation [54].

Polyacrylamide Gel

Like dextran beads, polyacrylamide is used mainly for protein separation by molecular biologists. The use of polyacrylamides as injectable filler materials was initiated in 1983, and they were used clinically in the Ukraine and China as Interfall [14] or “Amazing Gel” in thousands of patients. However, to date few clinical and scientific data have been published in Western literature [23]. Since Interfall’s patent expired, at least seven European companies are marketing polyacrylamides as dermal filler substances (Royamid, Argiform, Bioformacryl, OutLine, Aquamid, Evolution, Kosmogel). So far, they have been injected in large quantities for breast, buttock, and calf augmentation, in facial lipodystrophy and congenital malformations [14], and have been called “endoprotheses” [42]. If overcorrection occurs, the fluid can be withdrawn from the implant even after years. Reportedly, it has a half-life in the human body of >20 years. This may be true for large quantities; however, the injection of 0.1 cc Aquamid was resorbed in human skin within 9 months. The concentration of acrylamide monomers that can be toxic was reported to be <10 ppm or 0.04%. Side effects were enlarged lymphnodes in 10%, migration of gel in 3%, and edema in 2%. The U.S. Environmental Protection Agency classifies acrylamide as a medium-hazard probable human carcinogen. Even if there are few published reports [30], granuloma formation after Interfall implantation is well known in China since 1997 [14] and has to be expected in certain patients as with all other injectables.

Polyvinyl Gel Microspheres

The mixture of apparently slowly resorbable polyvinyl microspheres with a longer lasting polyacrylamide gel (Evolution) showed similar histological reactions to Aquamid within the first 6 months, and from then on was like Artecoll. Clinically and histologically it showed the least reactions and remained visible and palpable throughout the 9 months. Future clinical experience has to show whether late side effects are as high as with acrylamides.

Calcium-Hydroxylapatite Microspheres

Ca-hydroxylapatite is the primary component of bone and dents. In form of particles it was first used as onlay grafts for bone regeneration in dentistry. Ca-hydroxylapatite microspheres of 75–125 μm in diameter (Coaptite®) are injected as a bulking agent in urinary incontinence. It is highly biocompatible, causes little tissue reaction, well defined at the injection site, radio-opaque, and can therefore be used as a tissue marker (Radiance FN). In the skin and especially in the lip, it does not “remain soft” but exhibits a clear hardening of the implant, which resolves over time. Since March 2002, Radiance FN can be used “off-label” in the US for wrinkle treatment and lip augmentation. Since it disappeared from the skin within 12 months, it is a semi-permanent implant like many others (Aquamid, Dermalive, New-Fill, Reviderm) and not a “near-permanent solution”. While Radiance is well tolerated beneath wrinkles, it should not be recommended for lip augmentation. The concomitant movement of the orbicularis muscle in women during chewing compresses every injected strand to a lump!

Histologically, the calcium hydroxylapatite microspheres do not “provide a scaffold for tissue infiltration consistent with the form of the surrounding tissue”. Because of little tissue ingrowth [16, 43] and absence of granulation tissue, triamcinolone (Kenalog®) injections into Radiance lumps will be ineffective and should be omitted. In some patients, however, Radiance microspheres may induce a kind of foreign body reaction - as demonstrated by one histological picture in the company’s advertisement, which of course will react to intralesional corticosteroids.

In general, the histological examination of all samples showed distinctive morphological findings for each type of micro-implant, which can help distinguish different injected substances. The differential diagnosis could also be of medico-legal interest because adulterated or improper substances are sometimes injected fraudulently [54]. PMA-particles (Dermalive) showed multiple sharp edges and points taking on a “broken glass” appearance, whereas microspheres are devoid of any jagged or sharp edges that might serve as a continued source of irritation.

Complications

Besides well-known allergies, displacement, and granuloma formation, another potential complication of dermal filler substances was documented only recently [62]. Localized fat atrophies in the cheeks, similar to those seen in facial lipodystrophy after HIV treatment [11,57], occurred 2–3 months after the implantation of Restylane or New-Fill in the nasolabial folds of healthy patients. At 9 months, the implants could still be identified and were interspersed with giant cells and granulomatous tissue. The residues were encapsulated and surrounded by fat necroses and vacuoles. No explanation has been found for this side effect since there is no obvious link in the chemical structure of these two filler substances and HIV protease inhibitors.

Granulomas

All injectable filler materials cause normal foreign-body-type reactions that may develop into a foreign body granuloma in selected patients. Its cause is still unknown and no predictions can be made. Some of the patients reported a severe generalized viral or bacterial infection [37,41,53], vaccination, or local trauma some months before the appearance of the granulomas.

Granulomas occur in patients at a rate of 0.01% to 1.0% according to the chemical composition, shape, and surface structure of the particles [38]. They occur significantly less often after implantation of microspheres with a smooth surface (Artecoll, New-Fill, Evolution) [37,38] than after implantation of particles with irregular surface (Bioplastique, Dermalive) [6,54]. As would be expected, they also occur less frequently after injection of resorbable implants (collagen [29,45], hyaluronic acid [13,25,39-41,59]) compared to long-lasting implants [53,54].

Legal Aspects

In contrast to the FDA, Notified Bodies of the European Community do not require animal or clinical studies for the registration and approval of injectable filler substances or surgically introduced artificial implants. The European product quality control systems classify injectable dermal fillers as Medical Devices Class IIa (resorbable substances), and Class IIb (substances that cannot be reabsorbed). The FDA has determined that collagen is a Class III.A device and injected particles are a Class III.B device. In November 1997, a new provision was added to the Federal Food, Drug, and Cosmetic Act to allow any legally marketed, FDA-approved product to be administered for any condition within a doctor-patient relationship. This is called “off-label use” of an FDA-approved product.

The CE mark controls only Good Manufacturing Practice (GMP) of an injectable agent but does not guarantee a maximum of biological safety. Therefore, a central office similar to the FDA should be established in Europe to which all severe clinical side effects have to be reported. Some manufacturers report the complication rates as a percentage of treatments (Restylane, Hylaform, Dermalive)—most probably of syringes sold—, whereas other manufacturers report the side effects as percentage of treated patients [35]. Only a careful statistical analysis of these data will shed some light on the true incidence of side effects for each dermal filler substance.

Conclusions

The differences in histological reactions and in permanence lead to a classification of injectable filler substances into five types:

1. *Autologous fat* rarely is permanent and its fate is unpredictable. The mechanism for long-term survival of fat or stem cells has yet to be understood.
2. *Natural filler substances* such as collagen and hyaluronic acids are phagocytosed slowly with minimal histological reaction.
3. *Fluid filler substances*, such as fluid silicone and acrylamides, cause little fibrosis but can dislocate larger volumes through muscle movement and gravity; they are considered “dead implants.”
4. *Particulate materials* like PMA gravel and PLA microspheres are packed and induce minimal foreign body reaction and fibrosis. They are pure fillers and are slowly resorbed.
5. *Microspheres* from non-resorbable PMMA or resorbable dextran are stimulants for encapsulation and scaffolds of permanent or temporary connective tissue formation, considered “living implants.”

Host defense mechanisms reacted differently to each filler material; however, all substances—resorbable or nonresorbable—appeared to be clinically and histologically safe. None of the tested substances is without undesirable effects [1,46,52,55]. Since the cause of late inflammation or granuloma formation is not yet known, predictions can be not be made from early histological results for possible late reactions of the host to an individual filler substance.

Therefore, materials must be selected according to the needs of the individual patient. The patient should be informed and involved in the choice of resorbable or long-lasting filler substance. Hyaluronic acid and new collagen products such as Cymetra, Fascian, or CosmoDerm could not be demonstrated to last longer than bovine collagen. The development of a possibly disease- and allergy-free human recombinant collagen from yeast (Fibrogen, San Fran-

cisco) or cow milk (Cohesion Technologies, Palo Alto) has a long way to go. The search for the perfect permanent injectable material with maximum safety is ongoing. Time and a centralized registry of adverse events—similar to the registries for silicone breast implants—will bring improvement in efficacy and safety of new generation filler substances.

References

- Alster TS, West TB: Human-derived and new synthetic injectable materials for soft-tissue augmentation: Current status and role in cosmetic surgery. *Plast Reconstr Surg* **105**:2515, 2000
- Amard P: PLA (New-Fill) as management of lipoatrophy of the face. *Magazin Aesthet Surg* **1**:28, 2001
- Athanasίου KA, Niederauer GG, Agrawal CM, Landsman A: Applications of biodegradable lactides and glycolides in pediatry. *Implant Biomater* **12**:475, 1995
- Bendszus M, Klein R, Burger R, et al.: Efficacy of trisacryl gelatin microspheres versus polyvinyl alcohol particles in the preoperative embolization of meningiomas. *Am J Neurosurg* **21**:255, 2000
- Bent AE, Foote J, Siegel S, Faerber G, Chao R, Gormley EA: Collagen implant for treating stress urinary incontinence in women with urethral hypermobility. *J Urol* **166**:1354, 2001
- Bergeret-Galley C, Latouche X, Illouz Y-G: The value of new filler material in corrective and cosmetic surgery: DermaLive and DermaDeep. *Aesth Plast Surg* **25**:249, 2001
- Bigata X, Ribera M, Bielsa I, Ferrandiz C: Adverse granulomatous reaction after cosmetic dermal silicone injection. *Dermatol Surg* **27**:198, 2001
- Burres S: Recollagenation of acne scars. *Dermatol Surg* **22**:364, 1996
- Busso M: Soft tissue augmentation with Radiance FN. *Aesthetic Trends & Technologies* **2**(3): 2003
- Cahill KV, Burns JA: Volume augmentation of the anophthalmic orbit with cross-linked collagen (Zyplast). *Arch Ophthalmol* **107**:1684, 1989
- Carr A, Samaras K, Burton S, et al.: A syndrome of peripheral lipodystrophy, hyperlipidaemia and insulin resistance in patients receiving HIV protease inhibitors. *AIDS* **12**:F51, 1998
- Chan RW, Titze IR: Viscosities of implantable biomaterials in vocal cord augmentation surgery. *Laryngoscope* **108**:725, 1998
- Chen AL, Desai P, Adler EM, Di Cesare PE: Granulomatous inflammation after hylan g-f 20 viscosupplementation of the knee: a report of six cases. *J Bone Joint Surg (Am)* **84-A**:1142, 2002
- Cheng N-X, Wang Y-L, Wang J-H, Zhang X-M, Zhong H: Complications of breast augmentation with injected hydrophilic polyacrylamide gel. *Aesth Plast Surg* **26**:375, 2002
- Cohen SR, Holmes RE (2004) Artecoll: A longlasting wrinkle augmentation material. To be published in *Plast Reconstr Surg* 113:
- Drosbeck HP, Rothstein SS, Gumaer KI, Sherer AD, Slighter RG: *J Oral Maxillofac Surg* **42**:143, 1984
- Duffy DM: Injectable liquid silicone: new perspectives. In: Klein AW (Eds.) *Tissue Augmentation in Clinical Practice: Procedures and Techniques*. Marcel Dekker, New York, pp 237–267, 1998
- Duffy DM: The silicone conundrum: A battle of anecdotes. *Dermatol Surg* **28**:590, 2002
- Duranti F, Salti G, Bovani B, Calandra M, Rosati M: Injectable hyaluronic acid gel for soft tissue augmentation. *Dermatol Surg* **24**:1317, 1998
- Eppley BL, Summerlin D-J, Prevel CD, Sadove AM: Effects of positively charged biomaterial for dermal and subcutaneous augmentation. *Aesth Plast Surg* **18**:13, 1994
- Ersek RA, Beisang AA: Bioplastique. A new textured copolymer microparticle promises permanence of soft-tissue augmentation. *Plast Reconstr Surg* **87**:693, 1991
- Feretic C, Benakis P, Dimopoulos C, et al.: Endoscopic implantation of Plexiglas (PMMA) microspheres for the treatment of GERD. *Gastrointest Endosc* **53**:423, 2001
- Filatov AV, Mirolyubov SN: Contour plasty of maxillofacial soft tissues with biocompatible polyacrylamide gel (Russian). *Stomatologija (Mosk)* **77**:45, 1998
- Flint PW, Corio RL, Cummings CW: Comparison of soft tissue response in rabbits following laryngeal implantation with hydroxylapatite, silicone rubber and Teflon. *Ann Oto Rhino Laryngol* **106**:399, 1997
- Friedman PM, Mafong EA, Kauvar AN, Geronemus RG: Safety data of injectable nonanimal stabilized hyaluronic acid gel for soft tissue augmentation. *Dermatol Surg* **28**:491, 2002
- Garcia-Domingo MI, Alijotas-Reig J, Cistero-Bahima A, Tresserra F, Enrique E: Disseminated and recurrent sarcoid-like granulomatous panniculitis due to bovine collagen injection. *J Invest Allergol Clin Immunol* **10**:107, 2000
- Geile D, Zinner I, Erbel F, Schaefer M, Osterholzer G: Diagnosis and non-surgical treatment of faecal incontinence in the proctological practice. In: Fruehmorgen P, Bruch H-P Eds. *Non-Neoplastic Diseases of the Anorectum*. Kluwer Academic Publishers, Dordrecht, 2001
- Hallen L, Johansson C, Laurent C: Cross-linked hyaluronan (Hylan B gel): an injectable remedy for treatment of vocal fold insufficiency—an animal study. *Acta Otolaryngol (Stockholm)* **119**:107, 1999
- Hanke CW: Adverse reactions to bovine collagen. In: Klein AW (Eds.) *Tissue Augmentation in Clinical Practice. Procedures and Techniques*. Marcel Dekker, New York, pp 145–154, 1998
- Kazachkov EL, Fridman AB, Friss SA: Granulomatous pleurisy after mammoplasty induced by polyacrylamide gel. (Russian). *Arkh Patol* **60**:58, 1998
- Kinney BM, Hughes III CE: Soft tissue fillers: An overview. *Aesth Surg J* **21**:469, 2001
- Klein AW, Elson ML: The history of substances for soft tissue augmentation. *Dermatol Surg* **26**:1096, 2000
- Kolle FS: *Plastic and Cosmetic Surgery*. D Appleton, New York, pp 209–230, 1911
- Lemperle G, Hoehler H: Granulome nach Unterspritzung von Gesichtsfalten mit Teflon-Paste. In: Hoehler H (Ed.) *Plastische und Wiederherstellungschirurgie* Schattauer, Stuttgart, pp 335–340, 1975
- Lemperle G, Gauthier-Hazan N, Lemperle M: PMMA-microspheres (Artecoll) for long-lasting correction of

- wrinkles: Refinements and statistical results. *Aesth Plast Surg* **22**:365, 1998
36. Lemperle G: Hyaluronsäure zur Faltenunterspritzung. *Arzneimittel-, Therapie-Kritik* **3**:635, 2000
 37. Lemperle G, Romano JJ, Busso M: Soft tissue augmentation with Artecoll: 10-year history, indications, technique and complications. *Dermatol Surg* **29**:573, 2003
 38. Lemperle G, Legaz ME (2004) Biocompatibility of injectable microparticles. *Aesth Plast Surg*, submitted
 39. Lowe NJ, Maxwell CA, Lowe P, Duick MG, Shah K: Hyaluronic acid skin fillers: Adverse reactions and skin testing. *J Am Acad Dermatol* **45**:930, 2001
 40. Lupton JR, Alster TS: Cutaneous hypersensitivity reaction to injectable hyaluronic acid gel. *Dermatol Surg* **26**:135, 2000
 41. Manna F, Dentini M, Desideri P, De Pita O, Mortilla E, Mars B: Comparative chemical evaluation of two commercially available derivatives of hyaluronic acid (Hylaform from rooster combs and Restylane from streptococcus) used for soft tissue augmentation. *J Eur Acad Dermatol Venerol* **13**:183, 1999
 42. Mazzoleni F, Dominici C, Lotti T, et al.: Formacryl: Un nuovo biopolimero al servizio della medicina "piu un endoprotesi che un filler." *Dermatologia* **1**:13, 2000
 43. Misiek DJ, Kent JN, Carr RF: Soft tissue responses to hydroxylapatite particles of different shapes. *J Oral Maxillofac Surg* **42**:150, 1984
 44. Moscona RR, Bergman R, Friedman-Birnbaum R: An unusual late reaction to Zyderm I injections: a challenge for treatment. *Plast Reconstr Surg* **92**:331, 1993
 45. Morhenn VB, Lemperle G, Gallo RL: Phagocytosis of different particulate dermal filler substances by human macrophages and skin cells. *Dermatol Surg* **28**:484, 2002
 46. Naoum C, Dasou-Plakida D: Dermal filler materials and botulin toxin. *Int J Dermatol* **40**:606, 2000
 47. Narins RS, Brandt F, Leyden J, Lorenc ZP, Rubin M, Smith S: A randomized, double-blind, multicenter comparison of the efficacy and tolerability of Restylane versus Zyplast for the correction of nasolabial folds. *Dermatol Surg* **29**:588, 2003
 48. Neto MS, Passy S: Rellenamiento cutaneo y correccion de las deformidades del rostro con el uso de microsferas de PMMA—un nuevo enfoque. In: *Proceedings of the 28th Argentinian Congress of Plastic Surgery*, Cordoba, pp 1–8, 1999
 49. O'Connor KW, Lehman GA: Endoscopic placement of collagen at the lower esophageal sphincter to inhibit gastroesophageal reflux: a pilot study of 10 medically intractable patients. *Gastrointest Endoscop* **34**:106, 1988
 50. Olenius M: The first clinical study using a new biodegradable implant for the treatment of lips, wrinkles and folds. *Aesth Plast Surg* **22**:97, 1998
 51. Pannek J, Brands FH, Schewe J, Senge T: Particle migration following transurethral injection of carbon coated beads for stress urinary incontinence. *J Urol* **165**(Suppl 5):74, 2001
 52. Pollack S: Some new injectable dermal filler materials: Hylaform, Restylane, and Artecoll. *J Cutan Med Surg* **3**Suppl 4:S4–S29, 1999
 53. Rapaport MJ, Vinnik C, Zarem H: Injectable silicone: cause of facial nodules, cellulites, ulceration, and migration. *Aesth Plast Surg* **20**:267, 1996
 54. Requena C, Izquierdo MJ, Navarro M, et al.: Adverse reactions to injectable aesthetic microimplants. *Am J Dermatopathol* **23**:197, 2000
 55. Rudolph CM, Soyer HP, Schuller-Petrovic S, Kerl H: Foreign body granulomas due to injectable aesthetic microimplants. *Am J Surg Pathol* **23**:113, 1999
 56. Rubin JP, Yaremchuk MJ: Complications and toxicities of implantable biomaterials used in facial reconstructive and aesthetic surgery: A comprehensive review of the literature. *Plast Reconstr Surg* **100**:1, 1997
 57. Saint-Marc T, Partisani M, Poizot-Martin I, et al.: A syndrome of peripheral fat wasting (lipodystrophy) in patients receiving long-term nucleoside analogue therapy. *AIDS* **13**:1659, 1999
 58. Senet P, Bachelez H, Ollivaud L, Vignon-Pennamen D, Dubertret L: Minocycline for the treatment of cutaneous silicone granulomas. *Br J Dermatol* **140**:985, 1999
 59. Shafir R, Amir A, Gur E: Long-term complications of facial injections with Restylane (injectable hyaluronic acid). *Plast Reconstr Surg* **106**:1215, 2000
 60. Spenlehauer G, Vert M, Benoit JP, Boddaert A: In vitro and in vivo degradation of poly(D,L-lactide/glycolide) type microspheres made by solvent evaporation method. *Biomaterials* **10**:557, 1989
 61. Tomacic-Jeciz VJ, Merritt K, Umbreit TH: Significance of type and the size of biomaterial particles on phagocytosis and tissue distribution. *J Biomed Mater Res* **55**:523, 2001
 62. Voy E-D, Mohasseb J: Lipoatrophie als seltene Komplikation nach Auffüllung der Nasolabialfalten mit injizierbaren Implantaten. *Magazin Aesth Chir* **2**, 2002
 63. Whitehead WE, Wald A, Norton NJ: Treatment options for fecal incontinence. *Dis Colon Rectum* **44**:131, 2001